

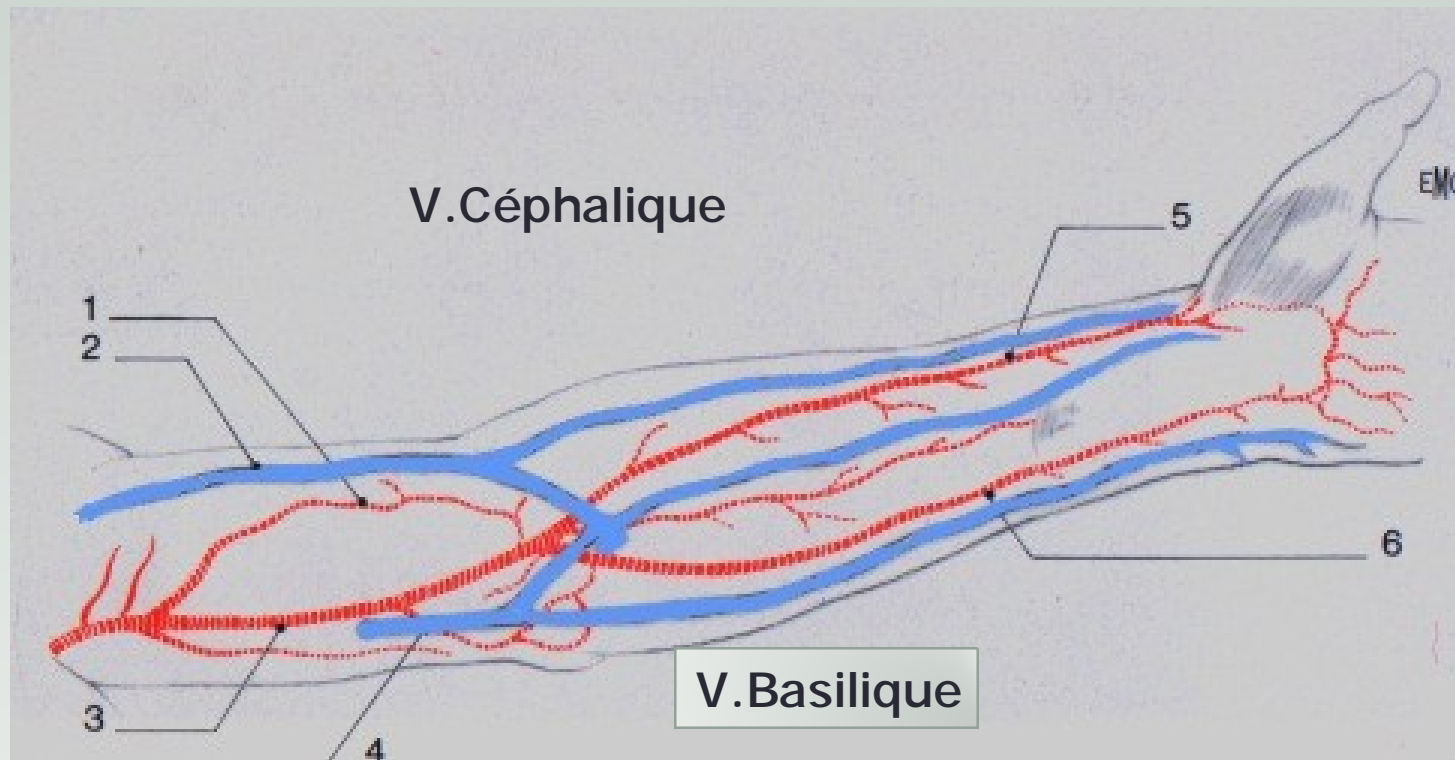
SFAV Montpellier
Jeudi 11 Juin 2015 13h05-13h15

ANATOMIE DES VAISSEAUX DU MS

Pierre Bourquelot

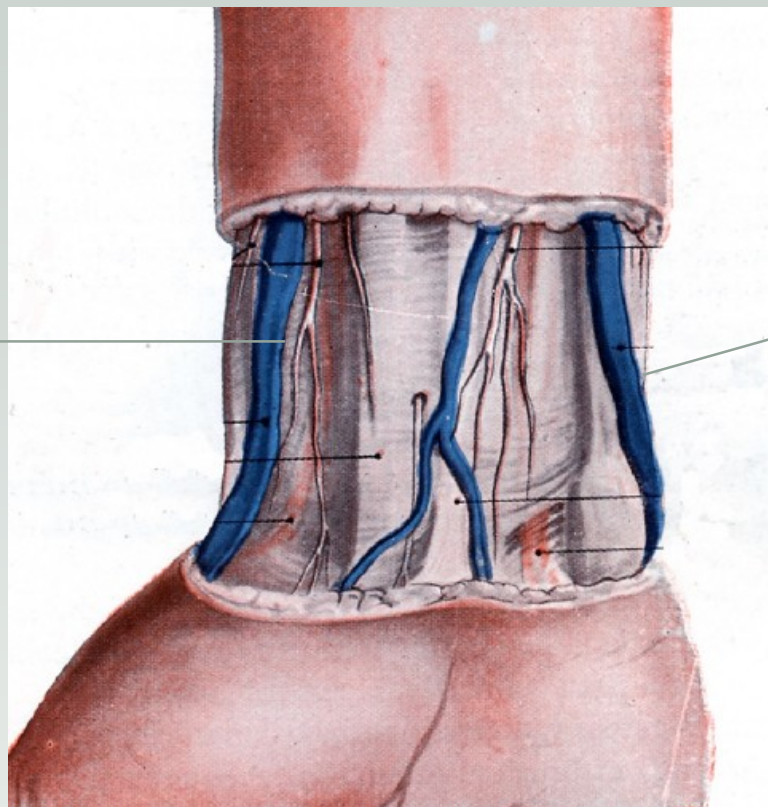


Artères et Veines



Poignet

V. Céphalique

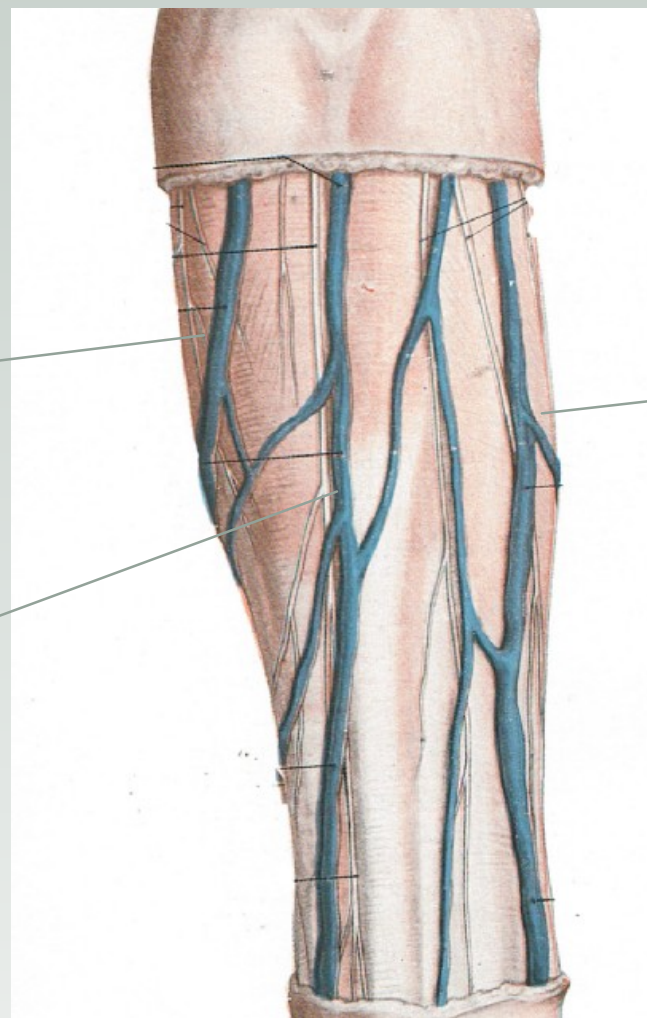


V. Basilique

Avant-Bras

V. Céphalique
accessoire

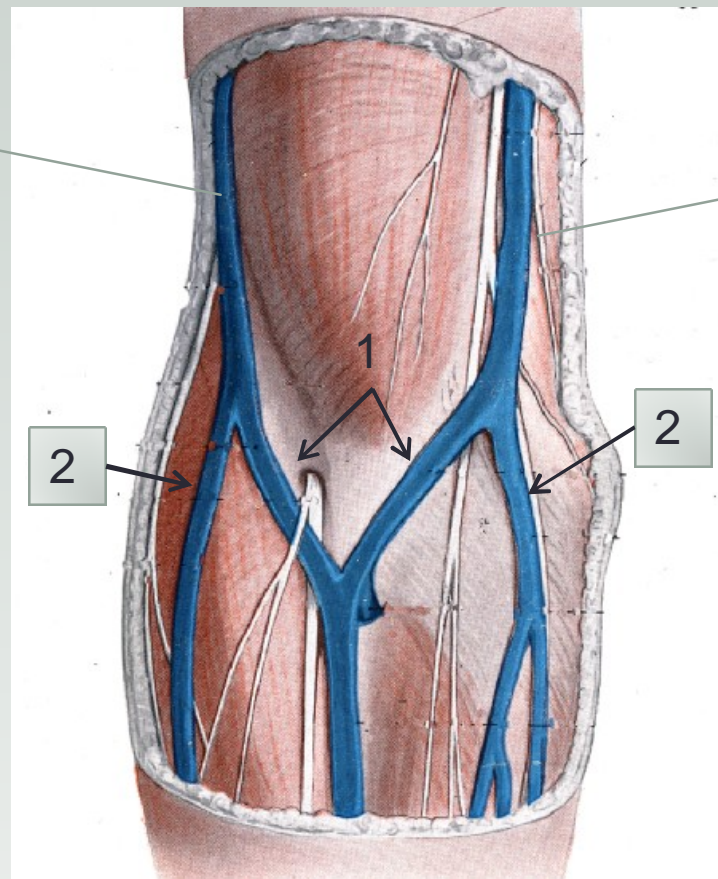
V. Céphalique
principale



V. Basilique

Coude

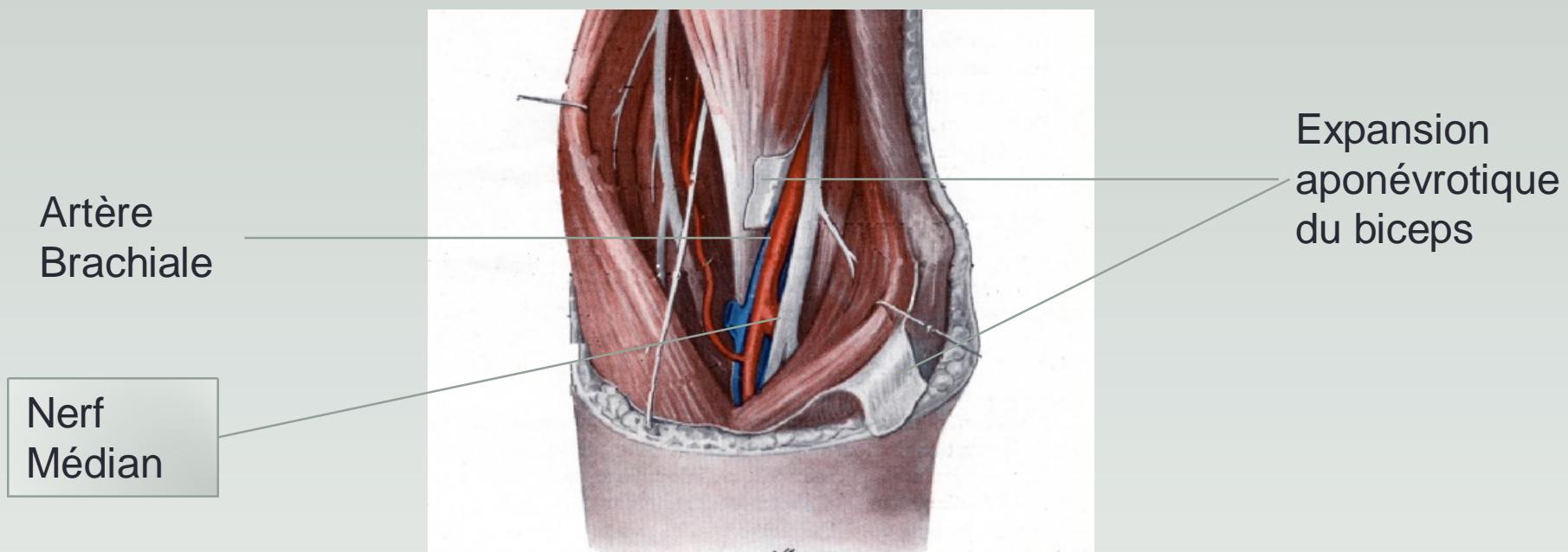
V. Céphalique



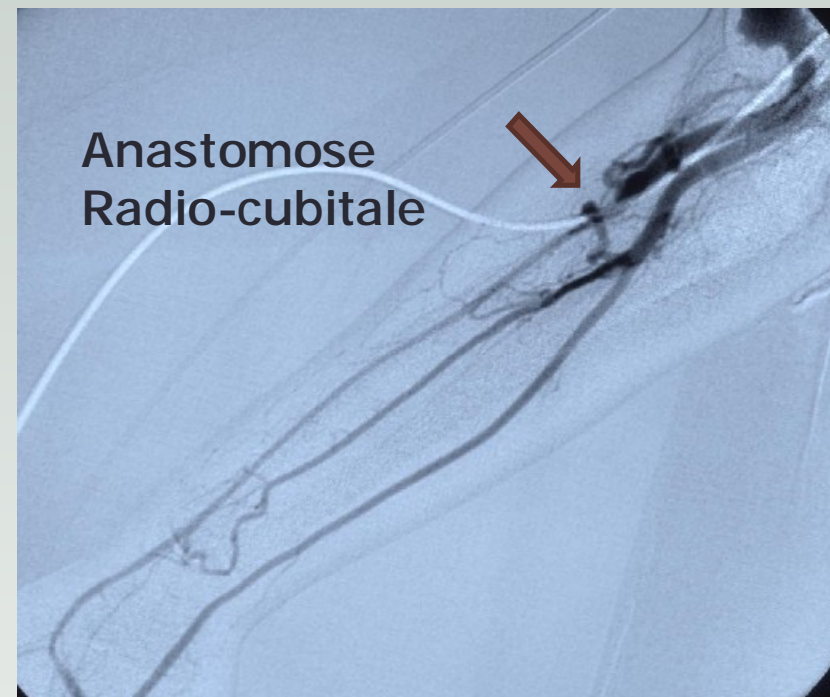
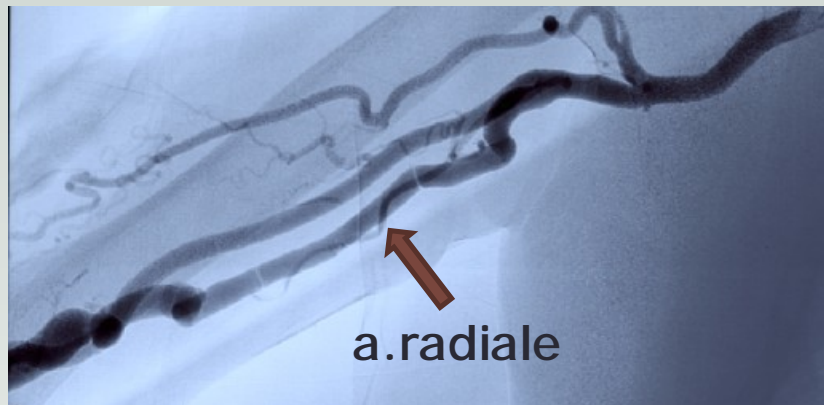
V. Basilique

1 : racines
médianes
2 : racines
latérales

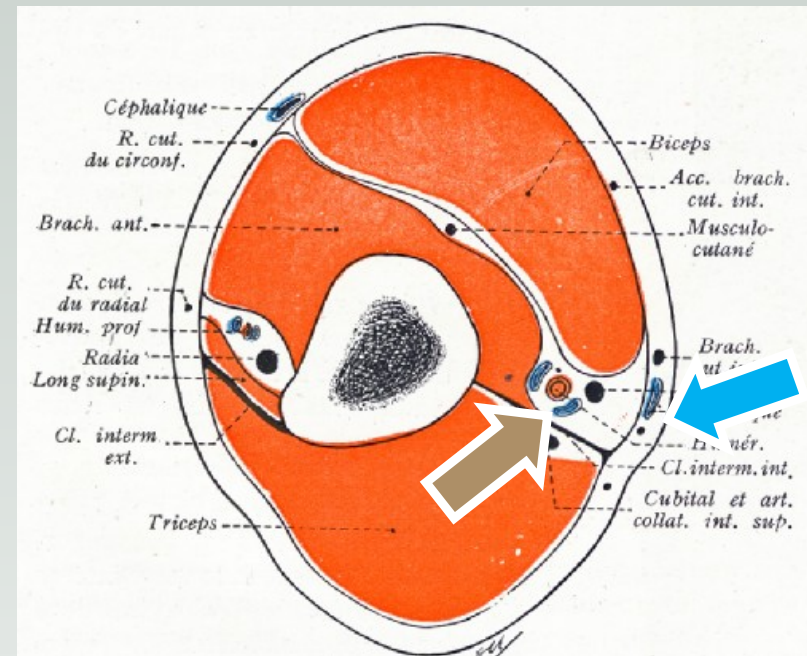
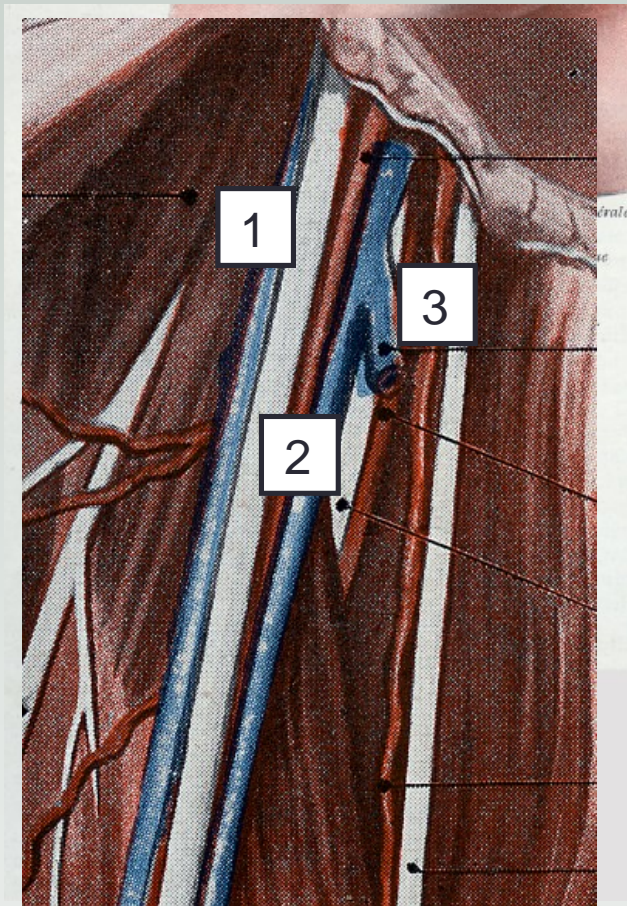
Coude



Bifurcation haute de l'artère brachiale

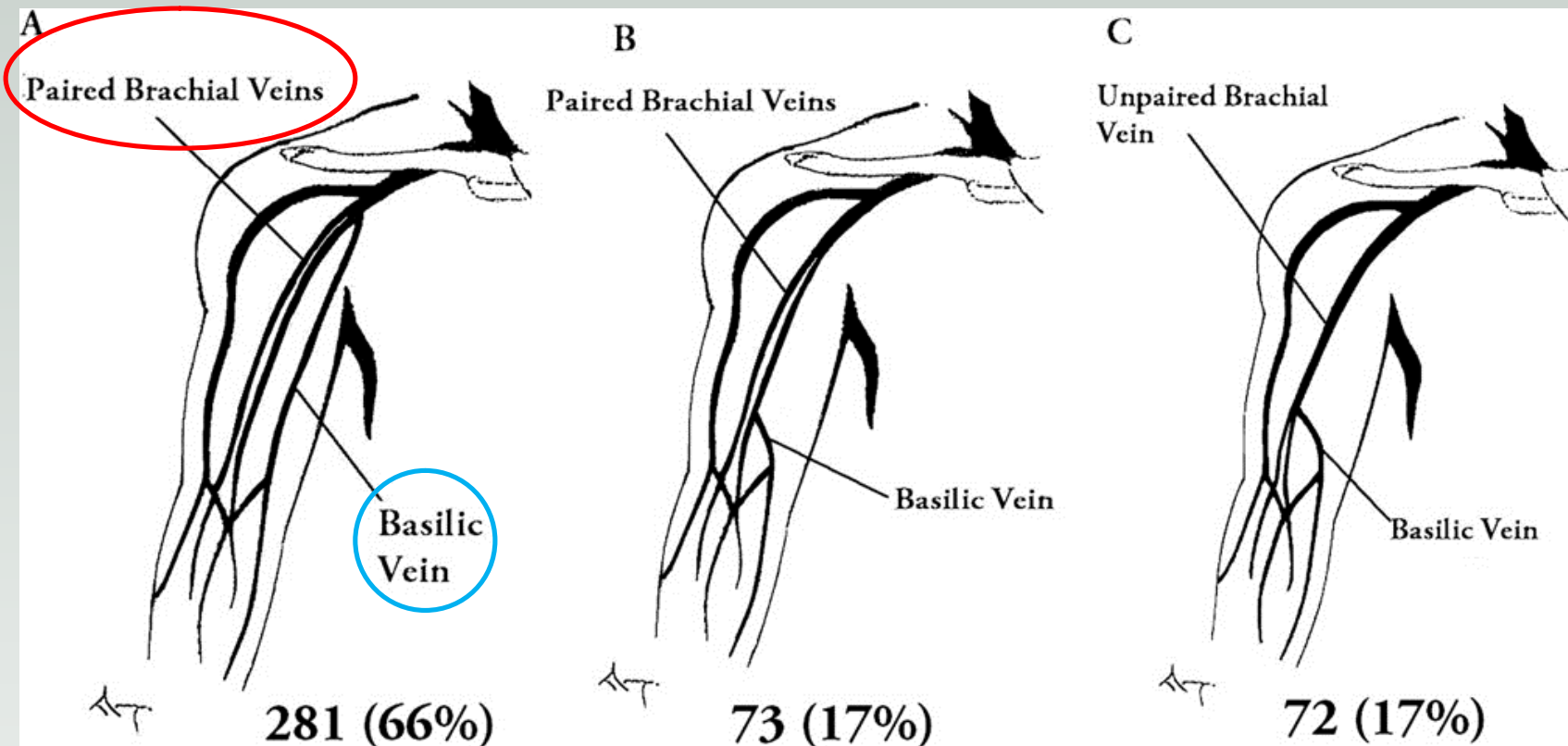


Bras



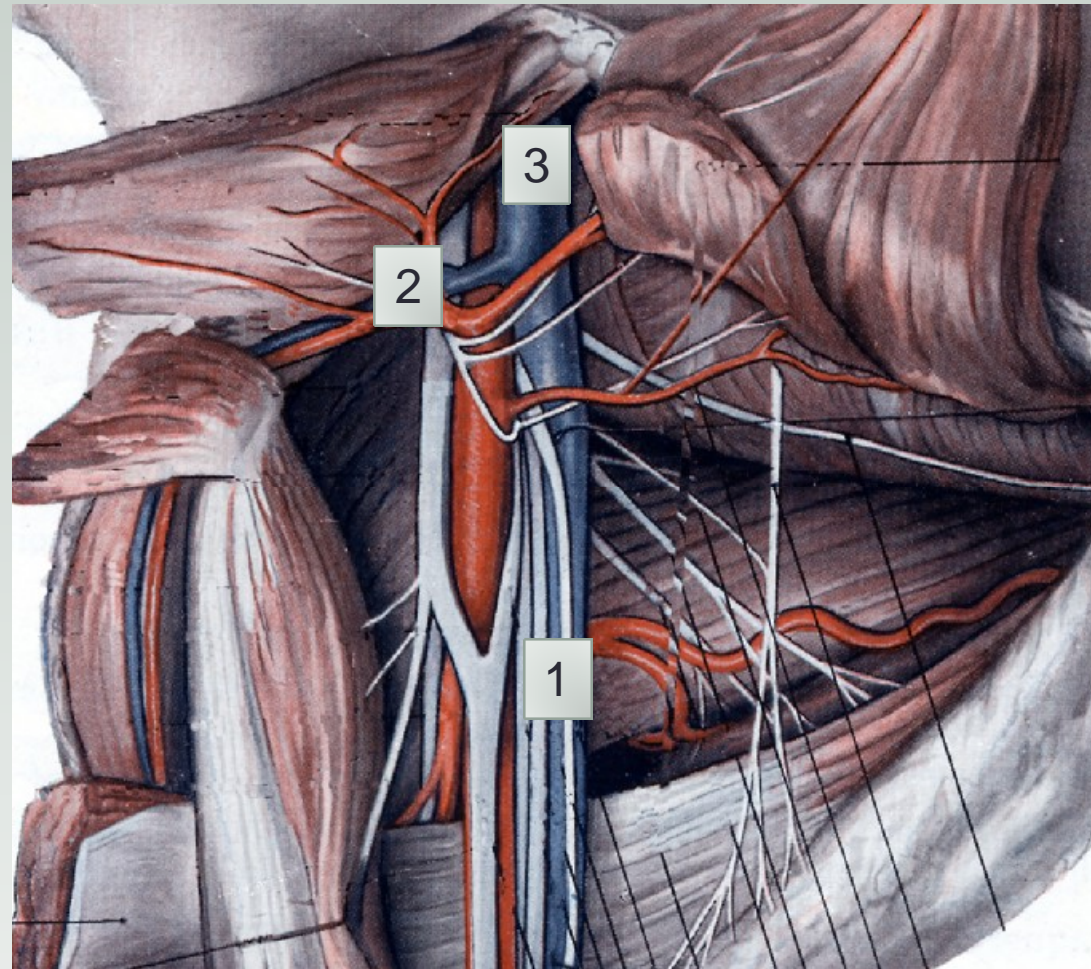
1 = V. Brachiale externe 2 = V.B. interne 3 = V. Basilique

Veines du bras, Anaya-Ayala JVS 2011



Creux axillaire

- 1 Veine axillaire
- 2 Veine Céphalique
- 3 Veine Sous-Clavière





pbourquelot@sfav.org